



# DACHSHUND Update

A PURINA PRO PLAN PUBLICATION DEDICATED TO DACHSHUND ENTHUSIASTS

VOLUME 19 | SPRING 2021



## ANGULAR LIMB DEFORMITIES

Potentially Painful & Crippling



# UNDERSTANDING ANGULAR DEFORMITIES IN DACHSHUNDS



Dachshund breeders and owners have likely heard about bowlegged syndrome, angular hock deformity, easty-westy feet, and Queen Anne fronts, terms describing potentially crippling angular limb deformities (ALDs). These inherited developmental abnormalities that occur during growth relate to the spatial misalignment of bones in a dog's legs resulting in joint incongruity and oftentimes painful lameness.

As Jan Anholt of Roserun Long-haired Dachshunds in Tucson, Arizona, describes the ALD pes varus, "Essentially one bone grows and one stops, which causes the bone to bow just before the growth plate closes."

Although ALDs have been recognized for more than 40 years, they continue to baffle breeders and owners when they see the legs and feet of their pick-of-the-litter puppy turn inward or outward. These otherwise happy, boisterous puppies often struggle to walk, sometimes dragging their feet or hopping along.

Dachshunds chosen to continue a breeding program, many slated as hopefuls for dog shows, field trials or companion sports, end up in pet homes. Because the mode of inheritance of the conditions is unknown, breeders could unwittingly proliferate the occurrence of ALDs in the breed.

ALDs affecting the rear legs are pes varus, which is Latin for "foot inward," an apt description of the bowlegged syndrome or angular

hock deformity, and pes valgus, meaning “foot outward” in Latin and describing the easty-westy appearance. Similarly, ALDs affecting the front legs are carpal varus, Latin for “wrist inward,” and carpal valgus, Latin for “wrist outward,” also known as a Queen Anne front or easty-westy. These conditions can be unilateral, occurring in one leg, or bilateral, seen in both legs. ALDs are diagnosed in all coat color and size varieties of Dachshunds. Anecdotally, these orthopedic disorders are believed to be occurring more commonly.

Deneice “Denny” Van Hook, DVM, president of the Dachshund Club of America Health & Welfare Trust Fund, says, “ALDs are cropping up in bloodlines you would not expect to see them in. Because the conditions are not apparent at 8 weeks of age, they are not recognized early and often puppies have been placed in homes before being diagnosed.”

Early detection and treatment of ALDs improve the prognosis for long-term health. While mild-to-moderate cases can be treated medically via supplementation, proper nutrition and weight manage-

## ANGULAR LIMB DEFORMITIES (ALDs) IN DACHSHUNDS

Veterinary orthopedic surgeon Dr. Bryan Torres of the University of Missouri says the most common ALD in Dachshunds is pes varus. He notes that any dog can develop an ALD and most are due to an injury or trauma; however, in Dachshunds a condition like pes varus rarely has a trauma-related pathology and is therefore believed to have a genetic component.

### Affecting Rear Legs

*Pes Varus* (Inward Foot): Also known as bowlegged syndrome or angular hock deformity, pes varus causes “toeing in” due to one or both hind legs turning inward

*Pes Valgus* (Outward Foot): Referred to as easty-westy, pes valgus is “toeing out” related to one or both hind legs turning outward

### Affecting Front Legs

*Carpal Varus* (Inward Foot): Similar to pes varus, carpal varus is “toeing in” caused by one or both front legs turning inward

*Carpal Valgus* (Outward Foot): Called a Queen Anne front or easty-westy, carpal valgus is “toeing out” due to one or both hind legs turning outward

ment, severe cases may require surgery. The surgical cost varies based on the geographical area and specialty clinic, though it averages \$5,000 per leg to correct a pes varus deformity.

“Surgical correction for ALDs should be considered with dogs having clinical signs of lameness

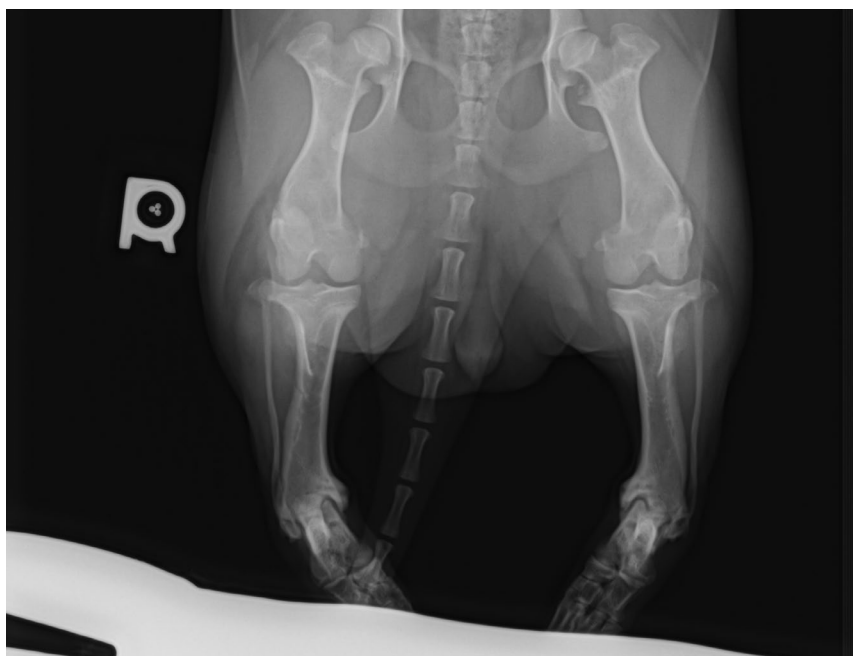
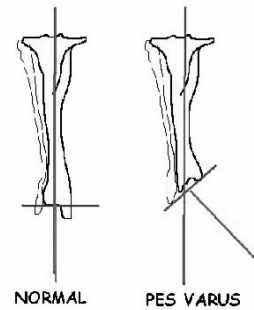


IMAGE PROVIDED BY DR. DAN BURKE

This radiograph shows the bowlegged deformity in a Dachshund with bilateral pes varus.

and pain,” says Bryan Torres, DVM, PhD, DACVS-SA, DACVSMR, associate professor of veterinary orthopedic surgery at the University of Missouri. “The key with these dwarf breeds is to identify what is ‘expected’ versus what is ‘excessive’ in regard to changes in the bones and limbs.”

Dachshunds and other chondrodysplastic or dwarf breeds, such as Basset Hounds, Pembroke and Cardigan Welsh Corgis, have a genetic predisposition for developing ALDs. Notably, ALDs also occur from growth plate injuries or trauma, though this is seldom the case with Dachshunds.



*These drawings depict differences between a normal distal tibia and one turned inward toward the body due to pes varus. The disease causes uneven growth of the tibia and a varus angulation of the distal tibia.*

IMAGE PROVIDED BY DR. DAN BURKE

“ALDs in Dachshunds are associated with chondrodysplasia,” says Danika Bannasch, DVM, PhD, the Maxine Adler Endowed Chair of Genetics at the University of California-Davis. “An *FGF4* retrogene insertion on canine chromosome 18 explains the short-legged phenotype known as chondrodysplasia, which contributes to orthopedic disorders such as ALDs by causing the stunted growth of certain bones.”

The *FGF4-18* retrogene insertion discovery was made in 2009 by researchers at the National Institutes of Health who were studying breed sizes and morphology.<sup>1</sup> A retrogene results from the retrotransposition of messenger RNA (mRNA). All cells have an RNA molecule that transcribes the DNA from the cell’s nucleus to the cytoplasm, or ribosomes, where it is synthesized into protein.

“Other factors besides having chondrodysplasia are likely to be contributing to the ALDs’ phenotype,” says Dr. Bannasch, who discovered the *FGF4-12* retrogene insertion linked to the causative variant of the chondrodystrophy phenotype.<sup>2</sup> “We do know that chondrodysplasia is associated with carpal valgus, while chondrodystrophy is not. How these two retrogenes may work together to exacerbate proper bone development leading to ALDs is unknown. Since most Dachshunds have two

## BANKING ON CHIC’S DNA REPOSITORY TO HELP ADVANCE ALD RESEARCH IN DACHSHUNDS

The Canine Health Information Center (CHIC) provides a DNA Repository for collecting and storing canine DNA samples to aid research aimed at reducing inherited diseases in dogs. A robust collection of blood samples from Dachshunds affected by angular limb deformities (ALDs) and unaffected Dachshunds would benefit future studies to learn more about the inherited conditions.

Deneice “Denny” Van Hook, DVM, president of the Dachshund Club of America Health & Welfare Trust Fund, says, “Dachshund breeders are increasingly focused on wanting to help identify the genetics of ALDs in the breed. Hopefully, one day research will enable breeders to significantly reduce or even eliminate ALDs in our dogs. The need for submitting blood samples from affected dogs and their sire, dam and littermates is imperative to these efforts.”

Eddie Dziuk, Chief Operating Officer of CHIC, says, “Thus far, CHIC has received fewer than 20 DNA samples from Dachshunds, and none indicates having any type of orthopedic disorder. If those involved in the breed believe there is sufficient interest and funding to look at the genetics of ALDs, then CHIC would allow them to bank DNA for this research.”

Founded by the Orthopedic Foundation for Animals in partnership with participating parent clubs, CHIC researches and maintains information on the health issues of specific breeds. Besides archiving blood samples, the DNA Repository collects genealogic and phenotypic information on individual dogs. The goal is to expedite the sample collection process and provide family groups for researchers studying diseases. Ultimately, breeders benefit when DNA-based disease tests become available to help them make responsible breeding decisions.

For information about CHIC, [click here](#), and to learn about the DNA Repository, [visit this link](#).





copies of both retrogenes, there may be additional genetic or environmental factors involved.”

Advising breeders on how to avoid producing dogs with an ALD can't be done. “Until more is known about the genetics behind each of the ALDs affecting Dachshunds, it is impossible to provide sure recommendations to breeders,” Dr. Bannasch says.

## DEALING WITH PES VARUS

Pes varus is the most common ALD seen in Dachshunds, according to Dr. Torres. It can be emotionally and financially draining, as Phyllis Meseroll and her husband, Michael Nothstein, of Swoope, Virginia, have found out. They are hoping for good luck on St. Patrick's Day when their Longhaired Standard Dachshund, Sunlight's Gold Rush, known as “Parker,” will have the first of two surgeries for bilateral pes varus at a specialty clinic in Annapolis Junction, Maryland. The handsome 9-month-old male is one of three puppies out of a litter they bred — and the

only Dachshund in their 20-plus years as breeders under the Sunlight prefix to have an ALD.

“Parker's condition was noticeable as soon as he started to walk at about 4 weeks old,” Meseroll says. “I thought of bowlegged syndrome right away. He would fall over and flop around as he tried to walk. Now, he hops using his front feet at the same time as though he is doing the butterfly stroke.”

Parker's sire is DC Sunlight's Skyrocket NA SE, a black-and-tan male born in 1993 who passed away in 2009 at 16 years of age. “Duxel,” as he was called, was bred four times during his lifetime, never producing a pup with an ALD.

“We had collected Duxel, as we hoped to use him for breeding when the right bitch came along,” Meseroll says. “He produced pups with fantastic rears.”

Unfortunately, unbeknownst to the breeders, the genetic trait for pes varus was lurking behind the breeding. “Most of the dogs in Duxel's bloodline and the breeders

---

“Until more is known about the genetics behind each of the ALDs affecting Dachshunds, it is impossible to provide sure recommendations to breeders.”

Danika Bannasch, DVM, PhD, the Maxine Adler Endowed Chair of Genetics at the University of California-Davis

---



“Parker,” a 9-month-old male Longhaired Dachshund, is having surgery to correct bilateral pes varus. The inset photo shows the bowlegged appearance of his rear legs that will be straightened during the surgical procedure.



as well have passed away,” Meseroll says. “It was a big surprise to learn that there were suspected carriers in the dam’s bloodline, as her breeder had never produced a pup with pes varus in nine generations of breeding.”

The bowlegged appearance of a dog with pes varus is usually the first clinical sign. It occurs when the growth plate of the distal tibia, or shinbone, closes prematurely. This causes asymmetrical growth of the tibia and an inward, or varus, angulation of the distal tibia. Because the

distal portion of the affected tibia is not level to the ground, though the lateral side is, the affected leg looks bowlegged.

All bones have growth plates, called epiphyseal plates. Immature, noncalcified cells comprise the soft, spongy matter that makes up young bones. As a puppy matures, the long bones of the legs grow from immature cells located at the end of the bones. When dogs are around 8 to 11 months of age, the distal epiphyseal growth plates close, a process in which they mineralize or become hard with calcium and minerals. Until these growth plates close, the bones continue to grow in length.

In the early stages of pes varus, when a dog puts weight on an affected leg, the body’s center of gravity shifts toward the side of the affected leg. Viewed from behind, the heel is in the inward position. As the tibial deformity progresses, a dog may become lame.

Pes varus usually occurs in Dachshunds between 4 and 6 months of age and ranges from mild to severe. Those with a mild case may show no clinical signs, though the younger the age in which the growth plate closes, the more severe the deformity.

“Patients that have lameness typically need surgery to straighten the leg and to help get the loading of the joint as close to normal as possible,” says Dr. Torres of the University of Missouri. “Without treatment, dogs can develop arthritis in affected joints as they age. On the other hand, mildly and some moderately affected dogs adapt well with seemingly no pain or limitation in their ability to get around.”

Surgery to correct pes varus — the procedure Parker is having — is an opening-wedge osteotomy. “We essentially make a cut in the bone, straighten out the bone and put either a bone plate on the inside of the tibia or use an external skel-



## PES VARUS FACEBOOK GROUP

Jan Anholt of Roserun Longhaired Dachshunds in Tucson, Arizona, co-founded a [Facebook group dedicated to pes varus](#) in 2011 after she bought a black-and-tan Longhaired Standard Dachshund puppy named “Charm” affected with the disorder. Today, there are 1,000 members from around the world who discuss the condition and share their experiences.

“For a long time, Dachshund breeders did not know what pes varus was,” Anholt says. “Some of the top-winning and top-producing dogs carry the gene for pes varus. In some cases, people know a dog is a carrier for pes varus and still breed the dog. Our goal is to educate people about pes varus without pointing fingers.”

etal fixator to stabilize the bone,” explains Dr. Torres. “As the bone is straightened, a pie-shaped wedge is created and in some cases bone graft is used to help encourage and speed bone healing.

“Three weeks before Parker’s surgery, a 3-D scan will be taken of his leg,” says Meseroll. “This will help the surgeon to measure the deformity and correct it. He will wear an external fixator for six to eight weeks. During this time, I am to walk him on leash, allowing him to put weight on the leg. Surgery for the second leg will be done after the first leg heals and the fixator is removed.”

The encouraging news is that once Parker’s surgeries are completed and he is on the mend, the

outlook for his being able to participate in normal activities is good. “After surgery, he can probably do almost anything including agility and field trials,” Meseroll says excitedly.

Meseroll and her husband feel fortunate that they have the funds available to cover the more than \$10,000 needed for Parker’s surgeries and related treatment costs. They worry that other people may not have the money to afford the corrective surgery. “This has been a lot to go through,” Meseroll says. “We may get out of breeding because of this. The best we can do for our dogs is to work together to fund research that will help us better understand the genetic risks of ALDs like pes varus.” ■

---

## LOOKING TO REPRINT?

*Dachshund Update* articles may be reprinted provided the article is used in its entirety and in a positive manner. To request permission to reprint this article, please contact the editor at: Barbara.Fawver @purina.nestle.com. Reprints should include the following attribution: Used with permission from the *Dachshund Update*, Nestlé Purina PetCare.

---



PHOTO: LESLIE NEWING

<sup>1</sup> Parker HG, VonHoldt BM, Quignon P, et al. An Expressed *FGF4* Retrogene Is Associated with Breed-Defining Chondrodysplasia in Domestic Dogs. *Science*. 2009;325:995-998.

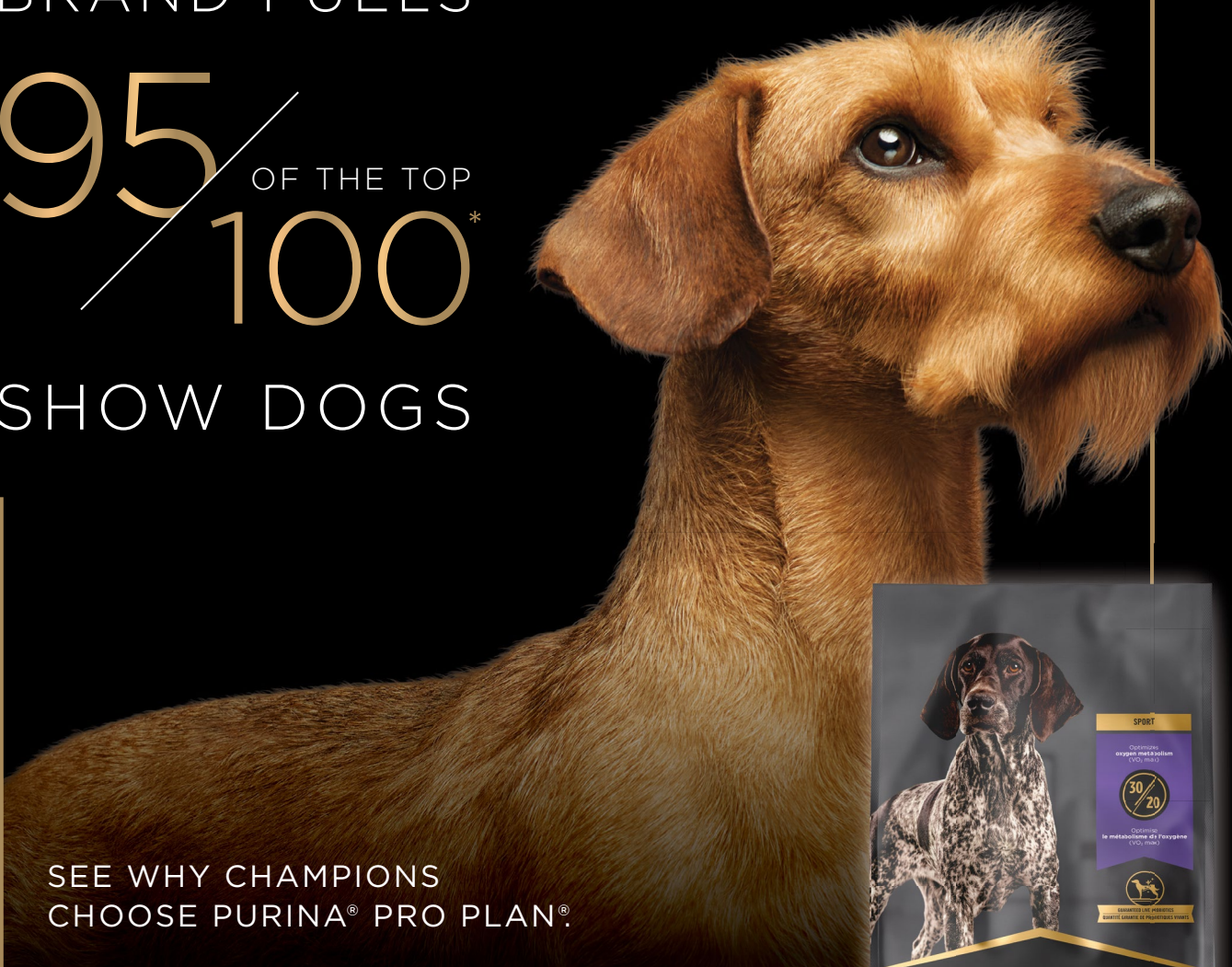<sup>2</sup> Brown EA, Dickinson PJ, Mansour T, et al. *FGF4* Retrogene on CFA12 Is Responsible for Chondrodystrophy and Intervertebral Disc Disease in Dogs. *PNAS*. 2017;114(43):11476-11481.

Purina appreciates the support of the Dachshund Club of America and particularly Deneice “Denny” Van Hook, DVM, president of the Dachshund Club of America Health & Welfare Trust Fund and member of the DCA board of directors, in helping to identify topics for the *Dachshund Update*.

ONLY ONE  
BRAND FUELS

95 / 100<sup>\*</sup> OF THE TOP

SHOW DOGS



SEE WHY CHAMPIONS  
CHOOSE PURINA® PRO PLAN®.

SUPPORTS  
**IMMUNE SYSTEM**  
DURING TRAVEL  
& COMPETITION

HELPS KEEP  
**SKIN & COAT**  
IN EXCELLENT  
CONDITION

HELPS OPTIMIZE  
**OXYGEN METABOLISM**  
FOR INCREASED  
STAMINA



[proplansport.com](http://proplansport.com)

EXCLUSIVELY AT PET SPECIALTY AND ONLINE RETAILERS

\*Dog News Magazine Top 100 Dogs based on AKC All-Breed Competition and RBIS through 12/31/20.  
The handler or owner of these champions may have received Pro Plan dog food as Purina ambassadors.

Purina trademarks are owned by  
Société des Produits Nestlé S.A.



Your Pet, Our Passion.®